# Study of Pathophysiological Effects of the Nematode Parasite *Eustrongylides* sp. on Freshwater Fish *Channa punctatus* by Hematology, Serum Biochemical, and Histological Studies

## Hematoloji, Serum Biyokimyasal ve Histolojik Çalışmalarla Tatlısu Balığı, *Channa punctatus* Üzerine Nematod Parazit *Eustrongylides* sp.'nin Patofizyolojik Etkileri

Ivy Kundu[1], Probir Kumar Bandyopadhyay[1], Dipak Ranjan Mandal[2], Gözde Gürelli[3]

[1]Department of Zoology, Kalyani University, Parasitology Laboratory, Kalyani-741235, West Bengal, India
[2]Sidho-Kanho-Birsha University, Purulia -723104, West Bengal, India
[3]Department of Zoology, Faculty of Sciences and Arts, Kastamonu University, Kastamonu, Turkey

**ABSTRACT**

**Objective:** The aim of this study was to study the pathophysiological effects on *Channa punctatus* due to the nematode parasite *Eustrongylides* sp.
**Methods:** A total of 250 fish were examined during the period January 2012–2014. Hematological, serum biochemical, histological, and scanning electron microscopic studies were performed on normal and infected hosts to study the effects caused by the nematode.
**Results:** The mean values of red blood corpuscle [RBC] count, hematocrit, and hemoglobin were significantly higher (P<0.01) in noninfected fish, while the values of white blood corpuscle [WBC] count, mean corpuscular volume [MCV], and mean corpuscular hemoglobin [MCH] were significantly higher (P<0.01) in infected fish. In infected fish, the average values of aspartate amminotransferase [AST] (416 $UL^{-1}$), alanine amminotransferase [ALT] (73.35 $UL^{-1}$), alkaline phosphatase [ALP] (161.6 mg $dl^{-1}$), and cholesterol (154.82 mg $dl^{-1}$) were significantly higher (P<0.01) than those in noninfected fish. Significant differences were also observed in total protein and glucose levels between the infected and noninfected fish. Histological and scanning electron microscopic studies of the host tissues revealed a series of pathological changes and mechanical damage.
**Conclusion:** It can be concluded that *Eustrongylides* sp. has a significant impact on its host and thus the parameters outlined in the present paper may be employed as tools in monitoring the health status of fish in culture practices. *(Turkiye Parazitol Derg 2016; 40: 42-7)*

**Keywords:** Abdominal cavity, *Channa punctatus*, *Eustrongylides* sp., nematode, pathophysiological studies.

**Received:** 10.10.2015 **Accepted:** 30.12.2015

**ÖZ**

**Amaç:** Bu çalışmanın amacı nematod parazit *Eustrongylides* sp.'nin *Channa punctatus* üzerine patofizyolojik etkilerini araştırmaktır.
**Yöntemler:** Toplam 250 balık Ocak 2012-2014 süresi boyunca araştırılmıştır. Nematodun sebep olduğu etkiyi araştırmak için, normal ve enfekte konaklar üzerine hematolojik, serum biyokimyasal, histolojik ve taramalı elektron mikroskop (scanning electron microscope) çalışmaları uygulanmıştır.
**Bulgular:** Parazitle enfekte balıklarda WBC (beyaz kan hücresi) sayımı, MCV (ortalama hücre yoğunluğu), MCH (ortalama hücre hemoglobini)'nin değerleri anlamlı şekilde daha yüksek (P<0,01) iken, enfekte olmayan balıklarda RBC (kırmızı kan hücresi) sayımı, hematokrit ve hemoglobinin ortalama değerleri anlamlı şekilde daha yüksektir (P<0,01). Enfekte balıklarda, aspartat aminotransferaz [AST] (416 $UL^{-1}$), alanin aminotransferaz [ALT] (73,35 $UL^{-1}$), alkalin fosfataz [ALP] (161,6 mg $dl^{-1}$) ve kolesterol (154,82 mg $dl^{-1}$)'ün ortalama değerleri enfekte olmayan balıklarınkinden anlamlı olarak daha yüksektir (P<0,01). Anlamlı farklılıklar enfekte ve enfekte olmayan balıklar arasında toplam protein ve glukoz seviyelerinde de gözlenmiştir. Konak dokuların histolojik ve taramalı elektron mikroskobu çalışmaları bir seri mekanik zarar ve patolojik değişiklikleri açığa çıkarmıştır.
**Sonuç:** Bu çalışmadan *Eustrongylides* sp.'nin konağı üzerine anlamlı etkiye sahip olduğu sonucu çıkarılabilir ve, bu bulgular, yetiştiriciliği yapılan balıkların sağlık durumlarını izlemede araç olarak kullanılabilir. *(Turkiye Parazitol Derg 2016; 40: 42-7)*

**Anahtar Kelimeler:** Karın boşluğu, biyokimyasal çalışmalar, *Channa punctatus*, *Eustrongylides* sp., nematod

**Geliş Tarihi:** 10.10.2015 **Kabul Tarihi:** 30.12.2015

**Address for Correspondence / Yazışma Adresi:** Dr. Probir Kumar Bandyopadhyay E.mail: prabir0432@hotmail.com
DOI: 10.5152/tpd.2016.4551
*©Telif hakkı 2016 Türkiye Parazitoloji Derneği - Makale metnine www.tparazitolderg.org web sayfasından ulaşılabilir.*
*©Copyright 2016 Turkish Society for Parasitology - Available online at www.tparazitolderg.org*

## INTRODUCTION

The snake-headed freshwater fish *Channa punctatus* of the family Channidae has a wide geographical distribution and a high growth rate and contributes significantly to the fishery sector in India. It usually inhabits swamps, pools, and rice fields and is known for its nutritive and invigorating qualities (1). The air-breathing teleost, being carnivorous in nature, acts as an intermediate or final host of many helminth parasites. Potentially, all freshwater and brackish water fish may be affected by nematodes, with heavier infections likely in predatory fish, particularly for species utilizing fish as an intermediate or transient host (2). Parasitic infection in fish results in heavy mucous secretion and discoloration and in severe cases causes high mortalities, which results in huge economic losses to fisheries.

The nematodes cause damage to the hosts by depriving them of digested food and by feeding on host tissues, sera, or blood. In some cases, direct mechanical damage results from them fixing to host tissues and developing or migrating in them (3-5).

Among fish nematodes, *Eustrongylides* infection has attracted considerable attention as it has been reported in various regions of the world and these nematodes exhibit a great potential for transmission and pathogenicity (6-9).

*Eustrongylides* sp are pathogenic parasites of piscivorous birds transmitted through two intermediate hosts: aquatic oligochaetes and fish (10-12). In fish, these parasites are conspicuous as long, red, coiled individuals located in the body cavity or embedded in the muscle (13, 14). Unencysted larvae of these parasites migrate under the skin and in the muscles, causing extensive inflammation and necrosis. Encystation occurring in the viscera, namely liver, spleen, or gonads causes severe pathologic changes in the adjacent tissue (6). Hence, to maximize productivity and to reduce fish mortality due to diseases and parasites, continuous evaluation of the physiological status of the fish is essential in the fishery sector.

Blood parameter analyses have proven to be valuable tools for diagnosing the health status of fish as these indices provide reliable information on metabolic disorders, deficiencies, and the chronic stress status before clinical symptoms appear (15). Thus, hematological tests and the analysis of serum constituents have proven useful in the detection and diagnosis of metabolic disturbances and disease processes (16, 17). In response to ecological and physiological conditions, major changes occur in fish blood composition, such as fluctuations in the levels of red and white blood cells (RBC and WBCs, respectively), hormones, hematocrit, hemoglobin concentration, leukocytes counts, and other basic components. No significant report is available on the effects of *Eustrongylides* infection on hematology and the serum biochemical profiles of the host *Channa punctatus*.

Therefore, the aim of this study was (i) to characterize the hematological and serum biochemical indices of normal and infected fish and to establish a correlation between the studied blood parameters and (ii) to assess the pathological changes and mechanical damage caused in visceral organs using histological and scanning electron microscopic studies, respectively.

## MATERIAL AND METHODS

### Collection of fish specimens and helminth parasites

A total of 250 host fish, i.e. *Channa punctatus* (17–21 cm in length) weighing 50–75 g, were collected from fish farms in Naihati and Kalyani, West Bengal during the period of January 2012–2014 and were brought alive to the parasitology laboratory for examination. They were acclimatized and maintained in glass aquaria (100×60×50 cm) following standard procedures (1). Adult fish specimens of nearly similar weight and length were dissected in physiological saline (0.75% NaCl solution) for collecting helminth parasites. Collected nematodes were fixed in hot 70% ethanol after being washed thoroughly in normal saline, and then stored in labeled glass vials containing glycerine alcohol (1:3). For light microscopic examination, each nematode was cleared in lactophenol for morphological observation and identification. The relative parameters were measured and identification was performed using selected identification keys (5, 18, 19). The approval of Institutional Animal Ethics Committee, University of Kalyani was not taken since the experiment were made on commonly available edible fishes.

### Scanning electron microscopic study of tissues infected with nematodes

The tissues and helminth parasites from infected fish were collected and fixed in 2.5% glutaraldehyde solution prepared in 0.1 M sodium cacodylate buffer (pH 7.4) at 4°C. The samples were then dehydrated through with a series of alcoholic grades, followed by washing with absolute alcohol and amyl acetate mixture in 3:1, 2:2, and 1:3 ratios, and finally in 100% amyl acetate. The tissues were finally critical point dried using $CO_2$ in a HCP:2 Critical Point Dryer (Hitachi, Tokyo, Japan) coated with metallic gold in an IB-2 ion coater and examined in a Hitachi S-530 Scanning Electron Microscope at accelerating voltages of 15 and 20 KV (20).

### Histological studies

Samples of visceral organs, such as the liver, spleen, and intestine, collected from both normal and infected fish were fixed in Bouin's fixative for 24 h, and then dehydrated using ascending grades of alcohol, cleared in xylene, and finally embedded in paraffin wax. Processed tissue samples were serially sectioned at about 5 µm on a rotary microtome, and stained with hematoxylin-eosin (21). The sections were examined using a light microscope and photographed by a phase-contrast microscopic camera (Olympus CX 41).

### Hematology analysis

Blood samples were collected by the caudal puncture method were immediately transferred into EDTA-containing assay tubes at an approximate concentration of 5 mg/mL of blood (22). The blood samples were diluted with the appropriate diluting fluids for red blood corpuscle (RBC) and white blood corpuscle (WBC) counts and the counts were determined using an improved Neubauer hemocytometer and then calculated (22, 23). The packed cell volume (PCV) was determined by using a microhematocrit capillary tube (24). The hemoglobin content in erythrocytes was determined by using Sahli's hemoglobinometer. Absolute values, like mean corpuscular volume (MCV), mean corpuscular hemoglobin concentration (MCHC), and mean corpuscular hemoglobin (MCH), were calculated using standard formulas (25).

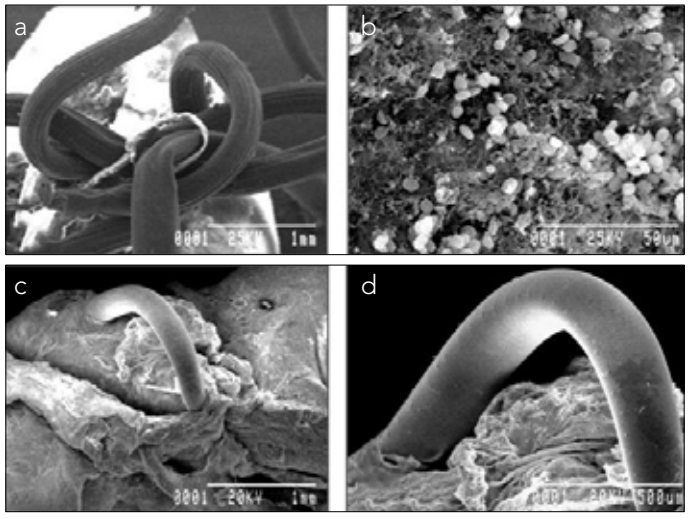


**Figure 1. a-d.** a: Nematode (*Eustrongylides* sp.) attached with the liver of the host *Channa punctatus*. b: Liver tissue damage indicated by the increase in number of RBCs in liver tissue infected with *Eustrongylides* sp. larvae. c and d: Attachment of the nematode with the intestine of the host.

### Biochemical analysis

The blood samples were collected in a clean, dry sample container (without anticoagulant) and were centrifuged at 2000 rpm for 5-6 min at 4°C. The supernatant containing the serum was collected and stored at −20°C prior to analysis. Biochemical tests were performed for determination of the serum glucose, cholesterol, total protein, albumin, aspartate amminotransferase (AST, E.C.2.6.1.1), alanine aminotransferase (ALT, E.C.2.6.1.2), and alkaline phosphatase (ALP, E.C.3.1.2.3.1). The total protein concentration in serum was estimated by the Biuret method (26). Albumin was determined by the bromocresol green method (27). Serum globulin was calculated by subtracting the concentration of albumin from that of the total protein, and the albumin/globulin ratio (A/G ratio) was calculated by dividing the albumin concentration over that of globulin (28).

AST and ALT activity were measured using a spectrophotometer with the 2.4 dinitrophenylhydrazine (2.4-DNPH) method (29). Alkaline phosphatase (ALP) was estimated by Kind and King's spectrophotometric method (30, 31). Serum cholesterol and glucose concentration were measured by a spectrophotometric method according to procedures described by Tietz (32) and Mendel et.al. (33), respectively.

### Statistical analysis

The experiments were conducted in triplicates. All the values are given as the mean ± standard error of the mean (S.E.M). The values of the hematological and biochemical data between the control and infected groups of fish blood were compared statistically by using student's t test (2-tailed). The mean values were compared at the 1% level of significance ($P<0.01$).

## RESULTS

### Macroscopic and microscopic observation

A total number of 250 fish were examined from January 2012 to January 2014, i.e., during the spawning and post-spawning season. Nematodes were recovered from the abdominal cavity, musculature, lumen of the stomach, and in the stomach wall. They were then identified as *Eustrongylides* sp based on larval anatomical characteristics, and most of them were encysted. The nematodes measured 17-20 mm in length and 0.19-0.23 mm in width.

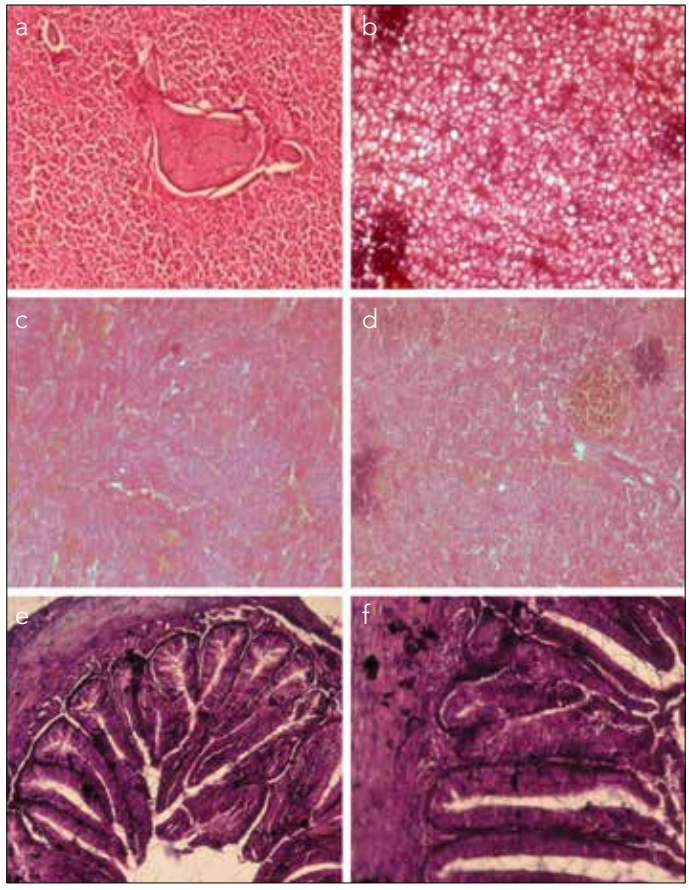


**Figure 2. a-f.** a: Histological section of liver from noninfected fish. b: Erythrocytes were observed in the hepatic tissue section, and part of the hepatic tissue was necrotic; numerous melanomacrophagic centers were also observed in the liver section of infected fish. c: Histological section of the spleen from noninfected fish. d: Spleen of infected fish mainly showing swelling in the thickened trabeculae and hemorrhage. e: Histological section of the intestine from a noninfected fish. f: Nematode occurrence in the intestine resulted in rupture of the villi, mucosa, submucosa, and even muscularis layers. Hypertropic and hyperplastic changes were also detected in the epithelial cells of mucosa.

### Scanning electron microscopic observations

SEM studies revealed the extent of the damage caused by the nematode in the visceral organs of the host *Channa punctatus*. Figure 1.A shows the attachment of the nematodes in the liver tissues that resulted in hemorrhage. Studies show the increase in number of RBC cells in liver tissue infected with *Eustrongylides* sp larvae Figure 1.B. Moreover, damage caused in the intestine of the host due to mechanical attachment and penetration of the nematode are illustrated in Figure 1.C and D. Furthermore, the scanning electron microscopic images of the nematode were used for taxonomic identification of the parasite.

**Table 1.** Effect of *Eustrongylides* sp. on some hematological parameters of *Channa puntatus* in comparison with noninfected and infected fish (Mean±SE). Values are expressed as the mean±standard deviation (SD) of 10 replicates. Student's 't' tests were performed noninfected and infected groups. The mean values were found to be significantly different at a 1% level of significance (P<0.01).

| Sl. No | Blood Parameters | Noninfected Fishes | | Infected Fishes | |
|---|---|---|---|---|---|
| | | Range | Mean±SD | Range | Mean±SD |
| 1. | RBC count(106 $\mu L^{-1}$) | 3.2-4.8 | 4.133±0.622 | 1.2-2.2 | 1.838±1.159 |
| 2. | WBC count (103 $\mu L^{-1}$) | 7.0-10.8 | 8.18±1.074 | 10.2-14 | 10.80±1.180 |
| 3. | Hg (g $dl^{-1}$) | 12.7-14.5 | 13.19±1.12 | 9.6-11.5 | 10.55±2.66 |
| 4. | PCV (%) | 41-46 | 43.458±4.00 | 22-33 | 32.195±5.57 |
| 5. | MCV (Ft) | 90.8-145 | 107.27±19.5 | 94.28-232.5 | 178.196±75.68 |
| 6. | MCH (pg) | 28.5-43.15 | 35.35±6.708 | 28.57-71.6 | 56.70±21.33 |
| 7. | MCHC (%) | 30.0-31.5 | 30.46±0.5217 | 28.2-29.5 | 29.4±1.059 |

RBC - Red blood corpuscle; WBC - White blood corpuscle;Hg- Hemoglobin; PCV - Packed cell volume; MCV - mean corpuscular volume; MCH - mean corpuscular haemoglobin; MCHC - mean corpuscular haemoglobin concentration.

**Table 2.** Effect of *Eustrongylides* sp. on some serum biochemical parameters of *Channa puntatus* in comparison with noninfected and infected fish (Mean±SE). Values are expressed as the mean±standard deviation (SD) of 10 replicates. Student's 't' tests were performed between noninfected and infected groups. The mean values were found to be significantly different at a 1% level of significance (P<0.01).

| Sl. No | Blood Parameters | Noninfected Fishes | | Infected Fishes | |
|---|---|---|---|---|---|
| | | Range | Mean±SD | Range | Mean±SD |
| 1. | Total protein (g $dl^{-1}$,mg $dl^{-1}$,$UL^{-1}$) | 2.5-6.0 | 4.473 ±1.31 | 1.2-3.09 | 2.279±0.8123 |
| 2. | Serum albumin (g $dl^{-1}$) | 2.5- 4.2 | 3 ±1.24186 | 0.4-2.5 | 1.44±1.203 |
| 3. | A/G | 1.4-1.9 | 1.572±0.139 | 0.33-1.3 | 0.819±0.429 |
| 4. | SGOT/AST($UL^{-1}$) | 140-315 | 190.9±89.019 | 213±640 | 416±172.55 |
| 5. | SGPT/ALT ($UL^{-1}$) | 30.2-36.42 | 34.167±1.067 | 65-85.5 | 71.8±13.71 |
| 6. | Alkaline phosphatase (mg $dl^{-1}$) | 125.47-145.35 | 130.60±2.91 | 150.56-170.65 | 165.8±32.43 |
| 7. | Glucose (mg $dl^{-1}$) | 49.6-87.07 | 66.10±21.5423 | 24.42-42.5 | 35.024±7.93 |
| 8. | Cholesterol (mg $dl^{-1}$) | 120.78-140 | 130.93±1.97 | 150-165.5 | 158.82±5.55 |

A/G ratio - albumin/globulin ratio; AST - aspartate amminotransferase; ALT - alanine aminotransferase; SGPT - Serum Glutamate Pyruvate Transferase; SGOT - Serum Glutamic Oxaloacetic Transaminase.

### Histological findings

Marked histopathological changes were recorded in the tissues of the liver, spleen, and intestine of the affected hosts. Inflammatory reaction, tissue necrosis, and circulatory disturbance were the main symptoms observed in the infected tissue sections. Hepatocytes were of irregular outline with abundant vacuolar space and the nucleus hardly visible. Penetration of the nematode disrupted the regular arrangement of the hepatocytes, which resulted in necrosis and hemorrhage, see Figure 2.B. Frequent and dispersed melanomacrophagic centers were observed in the sections of the infected fish.

The spleen of the infected fish mainly shows inflammation of the capillaries and hemorrhages, and numerous melanomacrophagic centers were observed, see Figure 2.D.

Nematode occurrence in the intestine resulted in the rupture of villi, mucosa, submucosa, and even muscularis layers. Hypertropic and hyperplastic changes were also detected in the epithelial cells of mucosa, see Figure 2.F, while the tissue sections from noninfected groups are normal in appearance and structure.

### Hematological analysis

The RBC count in the infected fish was significantly lower (P<0.01) than in noninfected fish. Conversely, the WBC count in infected fish was significantly higher (P<0.01) than in noninfected fish. Statistical analysis reveals that affected fish had significantly lower (P<0.01) hemoglobin and PCV levels, while the mean values of MCV and MCH were significantly higher (P<0.01). The mean values of MCHC showed nonsignificant differences in the studied fish. Values (mean, standard error, and ranges) of RBC and WBC counts, hemoglobin concentration, PCV, MCV, MCH, and MCHC of infected and normal fish are given in Table 1.

### Serum biochemical analysis

The mean values, standard error, and ranges of the serum biochemical parameters for both infected and noninfected fishes are summarized in Table 2. Significantly higher values were observed for ALT, AST, cholesterol, and ALP in infected fish than in noninfected fish (P<0.01). The total protein A/G ratio and glucose values were significantly lower (P<0.01) in infected fish in comparison to noninfected fish.

## DISCUSSION

This study reveals that *Eustrongylides* sp causes a series of biochemical, hematological, and pathological changes in the host fish. Glucopyruvic intoxication leads to a marked decrease in the glucose level of serum due to the consumption of an abundant amount of glucose content from the host by the nematode (34).

The liver acts as the main metabolic center for detoxification, biosynthesis, and excretion of cholesterol. Thus, increased levels of ALT, AST, and ALP in infected fish, as observed during the study, indicate impaired liver function (35) and extensive liver damage. Elevated levels of cholesterol indicate disorders of the lipid and lipoprotein metabolism, especially liver-impaired physiology (36).

In this study, hypoproteinemia with decreased levels of total serum protein (TSP) and albumin without marked changes in globulin level were observed. Parasitic infestation causes proteolysis of TSP, which results in the liberation of free amino acids and their utilization in numerous metabolic processes, like the tricarboxylic acid cycle (TCA), to meet the enhanced energy demand. The necrosis of hepatocytes results in a decline in the total protein level in serum, which may be due to the decrease in protein synthesis. The reason for the loss of protein from serum may also be attributed to the increased level of transaminase activity, indicating the rapid utilization of reserve foods like protein and carbohydrate under stress conditions (37, 38).

Blood acts as a pathophysiological reflector of the whole body (39, 40). Hence, hematological parameters are important in diagnosing the functional status of the fish infected with helminth parasites (41) and also to evaluate the physiological condition and nutritional status of the fish (42).

The RBC count, hemoglobin value, and packed cell volume were found to be significantly reduced in infected fish, which occurs as a result of the parasitic infestation that often leads to anemia (43). Furthermore, the parasites act as a stressor and during primary stages of stress, PCV changes due to the release of catecholamine, which can mobilize RBCs from the spleen (44) or induce RBC swelling as a result of fluid shift into the intracellular compartment (45).

The WBC count was found to be enhanced due to parasitic infestation, as WBCs are key components of innate immune defense and leukocytes are involved in the regulation of immunological function in the organism (46-48).

The MCV and MCH values recorded in infected fish were enhanced, which confirmed the pathological occurrence of pernicious anemia. The MCHC values showed a nonsignificant decline in infected fish in comparison with noninfected fish.

The histological changes appearing in visceral organs, such as the liver, spleen, and intestine, may be due to toxic substances released by the larvae, resulting in hydropic degeneration and the necrosis of normal cells. Such responses evoke inflammation and leukocytosis in the affected host. The severity of histopathological changes caused by this nematode is correlated with the depth of penetration within the host tissues along with the parasite burden.

The brown black pigments found in the vicinity of the parasites result from the activity of macrophages involved in the resorption and removal of foreign material. The pigment present in the melanomacrophagic centers consists mainly of lipofuscin and hemosiderin. In new hemorrhagic sites occurring due to the penetration and migration of helminths, hemosiderin-containing macrophages are usually found, while in chronic cases, darker pigment-containing macrophages are frequently encountered (49).

## CONCLUSION

The results of this study provide information regarding the characteristic features of hematological, biochemical, and histopathological changes in *Channa punctatus* due to *Eustrongylides* sp infection, suggesting that blood parameters and serum biochemical studies may be effective in monitoring the effects of nematode infestation in fish; this knowledge would be effective in fishery management programs.

---

**Ethics Committee Approval:** The approval of Institutional Animal Ethics Committee, University of Kalyani was not taken since the experiment were made on commonly available edible fishes.

**Informed Consent:** N/A.

**Peer-review:** Externally peer-reviewed.

**Author Contributions:** Concept - P.K.B.; Design - P.K.B.; Supervision - P.K.B.; Data Collection and/or Processing - I.K.; Analysis and/or Interpretation - I.K.; Literature Review - G.G ; Writer - I.K.,P.K.B and D.R.M.

**Acknowledgements:** The authors would like to thank the Dr Srikanta Chakraborty of University Science Instrumentation Centre, Burdwan University for technical assistance in scanning electron microscopy study. One of the authors (Ivy Kundu) is thankful to the Head, Department of Zoology, University of Kalyani, Nadia, West Bengal for providing necessary laboratory facilities.

**Conflict of Interest:** No conflict of interest was declared by the authors.

**Financial Disclosure:** The authors declared that this study has received no financial support.

---

**Etik Komite Onayı:** Deneyler genellikle mevcut yenilebilir balıklar üzerine yapıldığından, Kalyani Üniversitesi, Kurumsal Hayvan Etikleri Komitesinin onayı alınmamıştır.

**Hasta Onamı:** N/A.

**Hakem Değerlendirmesi:** Dış Bağımsız.

**Yazar Katkıları:** Fikir - P.K.B.; Tasarım - P.K.B.; Denetleme - P.K.B.; Veri Toplanması ve/veya işlemesi - I.K.; Analiz ve/veya Yorum - I.K.; Literatür Taraması - G.G.; Yazıyı Yazan - I.K., P.K.B., D.R.M.

**Teşekkür:** Yazarlar scanning electron mikroskobu çalışmasındaki teknik yardımları için (Burdwan Üniversitesi, Bilim Enstrümentasyon Merkezi) Dr. Srikanta Chakraborty'a teşekkürleri sunarlar. Yazarlardan Ivy Kundu, gerekli laboratuvar kolaylıklarını sağladığı için Kalyani Üniversitesi, Nadia, West Bengal, Zooloji Bölüm Başkanlığı'na teşekkür eder.

**Çıkar Çatışması:** Yazarlar herhangi bir çıkar çatışması bildirmemişlerdir.

**Finansal Destek:** Yazarlar bu çalışma için finansal destek almadıklarını beyan etmişlerdir.

## REFERENCES


1. Kundu.I, Bandyopadhyay PK, Mandal DR. Prevalence of helminth parasites infecting Channa punctatus Bloch, 1793 from Nadia district of West Bengal. IOSR-JAVS 2015; 8: 41-6.
2. Paperna I. Parasites infections and diseases of fishes in Africa-an update. CIF Technical Paper; 1996.
3. Bauer ON, Musselius VA, Nikolaeva VM, Strelkov Y. A. "Ichthyopathology idatelstvo pishchevaya promyshlennost". Moscow; 1977.
4. Dick TA, Choudhury A. Phylum Nematoda. In Woo PTK (Eds) Fish diseases and disorders. I. Protozoan and metazoan infections. UK: CAB international, Wallingford; 1995.
5. Moravec F. Parasitic Nematodes of Freshwater Fishes of Europe. Dordrecht/Boston/London: Kluwer Academic Publishers; 1994.
6. Paperna I.Hosts distribution and pathology of infections with larvaeof Eustrongylides (Dioctophymidae, Nematoda) in fish from East African lakes. J Fish Biol 1974; 6: 67-76. [CrossRef]
7. Moravec F, Nie P, Wang G. Some nematodes of fishes from central China, with the redescription of Procamallanus (Spirocamallanus) fulvidraconis (Camallanidae). Folia Parasitol 2003; 50: 220-30. [CrossRef]
8. Salgado-Maldonado G., Aguilar-Aguilar R., Caban˜ Ascaranza G. Helminth parasites of freshwater fishes of the Ayuquila River, Sierra de Manantlan Biosphere Reserve, West Central Mexico. Comp Parasitol 2004; 71: 67-72. [CrossRef]
9. Sattari M, Mokhayer B, Khara H., Nezami S, Shafii S. Occurrence and intensity of parasites in some bonyfish species of Anzali wetland from the southwest of the Caspian Sea. Bulletin of the European Association of Fish Pathologists 2007; 27: 54-60.
10. Karmanova E M. Dioctophymidea of Animals and Man and Diseases Caused by Them. Fundamentals of Nematology; 1968.
11. Measures LN. The development of Eustrongylides tubifex (Nematoda: Dioctophymatoidea) in oligochaetes. J Parasitol 1988; 74: 294-304. [CrossRef]
12. Measures LN. The development and pathogenesis of Eustrongylides tubifex (Nematoda: Dioctophy-matoidea) in piscivorous birds. Can J Zool 1988; 66: 2223-32. [CrossRef]
13. Mitchum DL. Parasites of Fishes in Wyoming. Wyoming Game and Fish Department, Cheyenne; 1995.
14. Overstreet RM. Presidential address: Flavor buds and other delights. J Parasitol 2003; 89: 1093-107. [CrossRef]
15. Bahmani M, Kazemi R, Donskaya P. A comparative study of some hematological features in young reared sturgeons (Acipenser persicus and Huso huso). Fish Physiol Biochem 2001; 24: 135-40. [CrossRef]
16. Shahsavani D, Mohri M, Gholipour Kanani H. Determination of normal values of some blood serum enzyme in Acipenser stellatus. Fish Physiol Biochem 2008; 36: 39-43. [CrossRef]
17. Aramli MS, Kalbassi MR, Nazari RM. Selected biochemical parameters in plasma of blood and semen of Persian sturgeon, Acipenser persicus. Comp Clin Path 2014; 23: 1241-5. [CrossRef]
18. Yamaguti S. The Nematodes of Vertebrates, in Systema Helminthum. Volume III. New York: John Wiley and Sons; 1961.
19. Anderson R C. Nematode Parasites of Vertebrates their Development and Transmission. 2nd Edition. CABI Publising; 2000. [CrossRef]
20. Eisenback. JD. A Comparison of Techniques Useful for Preparing Nematodes for Scanning Electron Microscopy. J Nematol 1986; 18: 479-87.
21. Bancroft JD, Stevens A, David RT. Theory and practice of histological techniques. 3rd Edition. Churchill Livingstone; 1990.
22. Blaxhall PC, Daisley KW. Routine haematological methods for use with fish blood. J Fish Biol; 1973: 771-81. [CrossRef]
23. Hesser EF. Methods for routine fish hematology. Progressive Fish-Culturist 1960; 22: 164-71. [CrossRef]
24. Wintrobe MM. Clinical Hematology. 4th Edition. Philadelphia: Lea and Febiger; 1965.
25. Dacie JV, Lewis SM. Practical Haematology. 5th Edition. London: J and A Churchill; 1975.
26. Doumas BT. Standards for total serum protein assays-a collaborative study. Clin Chim 1975; 21: 1159-66.
27. Gustafsson JE. Improved specificity of serum albumin determination and estimation of "acute phase reactants" by use of the bromocresol green reaction. Clin Chem 1976; 22: 616-22.
28. Coles EH. Veterinary Clinical Pathology. 4th Edition. Philadelphia: W B Sanders Company; 1986.
29. Reitman S, Frankel S. Colorimetric determination of glutamic oxaloacetic and glutamic pyruvic transaminases. Am J Clin Pathol 1957; 28: 53-6. [CrossRef]
30. King EJ, Armstrong AR. A convenient method for determining serum and bile phosphatase activity. Can Med Assoc J 1934; 31: 376-81.
31. Kind PRN, King EJ. Estimation of plasma phosphatases by determination of hydrolyzed phenol with amino antipyrine. J Clin Pathol 1954; 7: 330-2. [CrossRef]
32. Tietz NW. Textbook of Clinical Chemistry. Philadelphia: W B Saunders; 1986.
33. Mendel B, Kemp A, Myers DK. A colorimetric micromethod for the determination of glucose. Biochem J 1954; 56: 639-45. [CrossRef]
34. Von Brand T. Biochemistry of Parasites. London-New York: Academic Press; 1973.
35. Svoboda M, Kouril J,HamackovaJ, Kalab P,SavinaL, Svobodova Z, Vykusova B. Biochemical profile of blood plasma of tench (Tinca tinca L.) during pre and post spawing period. Acta Vet Brno 2001; 70: 259-68. [CrossRef]
36. Allen FM, Patrick JW, Roger TH. Blood biochemistry of the oyster toadfish. J Aquat Anim Health 2005; 17: 170-6. [CrossRef]
37. Bhakthavathsalam R, Srinivasa Reddy Y. Importance of protein metabolism during acute exposure of Anabas testudineus to lindane. Environ. Ecol 1984; 2: 194-8.
38. Goel KA, Gupta K. Haematobiochemical characteristics of H. fossilis under the stress of zinc. J Fish 1985; 32: 256-60.
39. Sharma G, Singh S. Studies on the effect of intoxicant indofil on the blood morphology of Channa punctatus (Bloch.). Bionotes 2004; 6: 20.
40. Sharma G and Singh S. Assay of some blood parameters of the fish, Channa punctatus (Bloch.) after intoxication of indofil. Bionotes 2006; 8: 21.
41. Joshi PK., Bose M., Harish D. Change in certain Haematological parameters in suliroid catfish Clarias batrachus (Linnaeus) exposed to cadmium chloride. Pollut Resour 2002; 21: 119-22.
42. Chagas EC, Val AL. Effeito da vitmina C no ganho de peso e em parametros hematologicos de tambaqui. Pesq Agropec Bras 2003; 38: 397-402. [CrossRef]
43. Martins ML, Tavares-Dias M, Fujimoto RY, Onaka EM, Nomura D T. Haematological alterations of Leporinus macrocephalus (Osteichtyes: Anostomidae) naturally infected by Goezia leporini (Nematoda: Anisakidae) in fish pond. Arq Bras Med Vet Zootec 2004; 56: 640-6. [CrossRef]
44. Wells RMG, Weber RE. The spleen in hypoxic and exercised rainbow trout. J Exp Biol 1990; 150: 461-6.
45. Chiocchia G, Motais R. Effect of catecholamines on deformability of red cells from trout: relative roles of cyclic AMP and cell volume. J Physiol 1989; 412: 321-32. [CrossRef]
46. Duthie GG, Tort L .Effects of dorsal aortic cannulation on the respiration and haematology of Mediterranean living Scyliorhinus canicula. Comp Biochem Physiol 1985; 81: 879-85. [CrossRef]
47. Gallardo MA, Sala-Rabanal M, Ibarz A, Padrós F, Blasco J, Fernández-Borra J, Sánchez J. Functional alterations associated with "winter syndrome" in gilthead sea bream (Sparus aurata). Aquaculture 2003; 223: 15-27. [CrossRef]
48. Ballarin L, Dall'Oro M, Bertotto D, Libertini A, Francescon A, Barbaro A. Haematological parameters in Umbrina cirrosa (Teleostei, Sciaenidae): a comparison between diploid and triploid specimens. Comp Biochem Physiol 2004; 138: 45-51. [CrossRef]
49. Roberts R. Melanin containing cells of teleost fish and their relation to disease. In Ribelin WE, Migaki G, editors. The Pathology of Fishes. Wisconsin: University of Wisconsin Press; 1975. p. 399-428.