



Investigation on the effects of pomiferin from *Maclura pomifera* on indomethacin-induced gastric ulcer: An experimental study in rats

İlyas Bozkurt¹ · Esra Dilek² · Hüseyin Serkan Erol³ · Ahmet Çakır⁴ ·
Ergin Hamzaoğlu⁵ · Murat Koç⁶ · Osman Nuri Keleş⁷ · Mesut Bünyami Halici³

Received: 16 December 2016 / Accepted: 27 April 2017 / Published online: 12 May 2017
© Springer Science+Business Media New York 2017

Abstract Previously, water extract of *Maclura pomifera* plant has been found effective on gastric damage. In this study, pomiferin product was purified from this plant by thin-layer chromatography method and its structure was elucidated by nuclear magnetic resonance methods. Its antiulcer effect was investigated on indomethacin-induced gastric damage in rats. For this study, a total of 36 Sprague Dawley female rats were divided into six groups such as healthy, control, reference, and three treatment groups ($n = 6$ each). Ranitidine (Ulcuran® 25 mg/ml vial) was used as reference. Biochemically, lipid peroxidation, and glutathione levels as well as superoxide dismutase, catalase, myeloperoxidase, and cyclooxygenase isoenzymes activities were measured in

stomach tissues. Comparing with healthy group, ulcerative area was observed in control group (only administered to indomethacin group). However, Ulcerative area in stomach tissues of rats administered of all doses of pomiferin and ranitidine showed significant decrease ($p < 0.05$). Also, there were significant changes at the antioxidant levels (lipid peroxidation, glutathione, superoxide dismutase, and catalase) and some important enzyme activities (myeloperoxidase, cyclooxygenase isoenzymes). We found that pomiferin was effective on gastric damage induced by indomethacin. This effect was thought to be caused by positive changes in the antioxidant system.

Keywords Antioxidant system · Indomethacin · *Maclura pomifera* · Pomiferin · Ulcer

Electronic supplementary material The online version of this article (doi:10.1007/s00044-017-1913-y) contains supplementary material, which is available to authorized users.

✉ Esra Dilek
edilek@erzincan.edu.tr
esrabayram25@gmail.com

- ¹ Department of Biochemistry, Faculty of Pharmacy, Ataturk University, Erzurum, Turkey
- ² Department of Biochemistry, Faculty of Pharmacy, Erzincan University, Erzincan, Turkey
- ³ Department of Biochemistry, Faculty of Veterinary, Ataturk University, Erzurum, Turkey
- ⁴ Department of Chemistry, Faculty of Science, Kilis 7 Aralık University, Kilis, Turkey
- ⁵ Division of Science Teaching, Faculty of Education, Gazi University, Ankara, Turkey
- ⁶ Animal production schools, Bozok University, Yozgat, Turkey
- ⁷ Department of Medical Histology and Embryology, Faculty of Medicine, Ataturk University, Erzurum, Turkey

Abbreviations

CAT	catalase
COX	cyclooxygenase
GIS	gastrointestinal system
GSH	glutathione
LPO	lipid peroxidation
MPx	myeloperoxidase
NMR	nuclear magnetic resonance
NSAID	nonsteroidal anti-inflammatory drug
PMF	pomiferin
ROS	reactive oxygen species
SOD	superoxide dismutase
TLC	thin-layer chromatography

Introduction

The use of nonsteroidal anti-inflammatory drugs (NSAIDs) and *Helicobacter pylori* infection commonly cause ulcer

disease (Yoshida et al. 2008; Sung et al. 2009). Although NSAIDs have a wide usage in the treatment of inflammation, fever and pain, their side effects especially on GIS stand out in relief (Hawkey 1990). And also, reactive oxygen species (ROS) have been shown to be effective in improving of pathogenesis in acute experimental gastric lesions induced by NSAIDs, ethanol, and stress. Therefore, many studies have been made on ROS contents, such as hydroxyl radicals (OH•), superoxide and singlet oxygen (Djahangiri 1968; Smith and Kvietyts 1988; Das and Banerjee 1993; Das et al. 1997; Navarrete et al. 1998; Odabasoglu et al. 2006). Because ROS attack unsaturated fatty acids in membranes, it cause lipid peroxidation (LPO) (Ames et al. 1993; Odabasoglu et al. 2006). When membrane proteins are damaged, the activities of enzymes and receptors, the membrane permeability and activation of cells decline. Moreover, if ROS attack to DNA, a cancer-inducing mutation may occur. Exactly at this point, antioxidant defense systems including antioxidant enzymes, drugs, and foods take an active role to prevent the toxic ROS effects (Ames et al. 1993; Bafna and Balaraman 2004).

Neutrophil infiltration in gastric mucosal tissues plays important role in the gastric ulcers pathogenesis (Nishida et al. 1998; Elliot and Wallace 1998). Myeloperoxidase (MPx) activity is checked to determine neutrophil infiltration in tissues (Yoshida et al. 1995; Coskun et al. 1996). On the other hand, role of cyclooxygenase isoenzymes in gastric mucosal defense system has clearly indicated in previous study. Both cyclooxygenase (COX)-1 and COX-2 isoenzymes protect the gastric mucosa with specific functions depending on the pathophysiological situation (Peskar 2001).

Recently, many drugs have been developed to treat ulcer (antacids, H₂ receptor antagonist, proton pump inhibitors) reduces the progression of the disease (Narayan et al. 2005). But, the use of these drugs does not constitute a complete treatment for ulcers. In fact, due to some side effects they give more dangerous consequences than ulcer (Farrow et al. 2000; Jalving et al. 2006; Gray et al. 2010; Marcus et al. 2010).

Since earliest times, the people widely have tried to treat ulcer with herbal treatments. Several molecules contained in the plants used to treat many diseases as ulcer have been isolated. And then, their effects such as antioxidant, anti-inflammatory, antibacterial, antiseptic, etc. have been determined on these diseases (Atalay et al. 2011; Chatterjee et al. 2013).

Maclura pomifera (Raf.) Schneid. is a tree and a member of the Moraceae family (Tsao et al. 2003). Different names commonly use for the fruit of *M. pomifera*, such as osage orange, horse apple, hedge apple, and road apple (Smith and Perino 1981). Many such studies, biological activities of extracts of the fruit, bark, leaves, seeds, and roots were reported. Moreover osajin and pomiferin (PMF), the two

major isoflavone constituents of the fruit, were reported to have many biological activities (Ozcelik et al. 2006; Kupeli et al. 2006; Florian et al. 2006; Son et al. 2007; Orhan et al. 2009; Carroll et al. 2010; Tran et al. 2011; Yang et al. 2011). *Maclura* species are widely used in folk medicine. In some study, it was reported that Comanche Indians in North America use *Maclura pomifera*'s roots in the treatment of an eye sore by boiling (Jones and Soderberg 1979; Kupeli et al. 2006). In Bolivia, the leaves and barks were used for uterine hemorrhage, the sap of the plant was used for the treatment of tooth pain (Bourdy et al. 2004).

In light of the above information, no report was found on the antiulcerogenic activity of PMF, which is a component from the fruit of the *Maclura pomifera*. Thus, we aim to investigate the antiulcerogenic activity of PMF on indomethacin-induced gastric damage in rats. At the same time, we aim to determine the enzyme activities, such as superoxide dismutase (SOD), MPx, catalase (CAT), COX-1, COX-2 and the levels of LPO and glutathione (GSH) in the stomach tissues of all treatment groups.

Materials and methods

Plant material

In all, 10–15 pieces of fruit were harvested from *M. pomifera* tree that it grows at a park in Kilis/Turkey in October by Murat KOC and a voucher specimen (M.Koç 1292) has been deposited in the herbarium of Department of Biology, Bozok University, Yozgat (Turkey). PMF substance was purified and identified by Ahmet CAKIR.

Extraction and isolation of PMF

The fresh fruits of *M. pomifera* (30 kg) were chopped into small pieces and dried in an oven at 60 °C. Dried fruits (6 kg) were extracted with ethyl acetate (5 × 2.5 L) at room temperature. The organic solvent was evaporated under reduced pressure and temperature (50 °C) using a rotary evaporator and viscous, yellow-greenish extract (114 g, % yield) were obtained.

The extract (45 g) was subjected to silica gel (350 g, 70–230 mesh) column chromatography (CC) using chloroform-ethyl acetate (8:2). The collected fractions (50 ml) were checked using thin-layer chromatography (TLC) with chloroform-ethyl acetate (8:2) eluent. Total 55 fractions were collected. When checked the fractions with TLC, the fractions 29 and later fractions contained a compound along with some minor impurities. Therefore, these fractions were combined and solvent was evaporated via rotary evaporator at low temperature and pressure (23.24 g). To isolate this metabolite, the fractions (20 g) were further subjected to

silicagel CC (200 g, 70–230 mesh) using chloroform-ethyl acetate (8:2). The fractions were collected in 50 ml volumes and checked with TLC using same eluent system, chloroform-ethyl acetate (8:2). According to TLC analyses, first 10–34 fractions contained a pure compound coded as PMF.

Nuclear magnetic resonance (NMR) spectra of PMF were recorded on a Varian Mercury 400 MHz spectrometer, operating at 400 MHz and 100 MHz for ^1H -NMR and ^{13}C -NMR, respectively, using acetone- d_6 . Chemical shifts were expressed in δ (in ppm) down field from TMS as an internal standard, and coupling constants were reported in Hz. The infrared spectra of PMF were determined on a Perkin Elmer Model 1600 fourier transform infrared spectrophotometer (Figs. S4–S9).

Animals

In this study, Sprague Dawley female rats, weighing 200–250 g, were used. The experiments were conducted according to the ethical norms approved by the Ethic Committee of Experimental Animal Teaching and Researcher Center (No: 36643897-124). A total of 36 rats were divided into six groups before the tests and kept under standard conditions.

Experimental ulcer model in rats

Method of Guidobono and colleagues (1997) was used to carry out experimental ulcer in rats (Guidobono et al. 1997). Gastro protective effects of herbal agent PMF and ranitidine on the indomethacin-induced gastric damage were investigated. The H_2 receptor blocker, ranitidine, was used as reference and their gastro protective effects were compared. PMF (100, 200, and 300 mg/kg body weight) and ranitidine (25 mg/kg body weight) were administrated orally to the assigned groups of rats. Three different doses of PMF were prepared by suspending in 1% carboxymethylcellulose-water solution. Five minutes after PMF and ranitidine at the indicated doses were administrated orally to the treatment and reference group, indomethacin (25 mg/kg body weight) was administrated orally to all animals except the healthy group.

Six hours after the administration of indomethacin, all animals were sacrificed using sodium thiopental (50 mg/kg). The rat stomachs were distinguished and opened along the greater curvature. And then they washed with serum physiological solution. The wideness of ulcer areas was determined using a magnifier and a millimeter paper.

Biochemical investigation of stomach tissues

In rat stomach tissues, the LPO and GSH levels, SOD, CAT, MPx, COX-1, and COX-2 enzyme activities were

determined after the macroscopic analyses. Firstly, the tissue homogenates were prepared. Therefore, stomach tissues were crushed with liquid nitrogen in a mortar. Then, the crushed tissues (0.5 g each) were taken into solution phase with 4.5 ml of appropriate buffer. The mixtures were homogenized on ice-bath by using an ultra-turraks homogenizer for 15 min. Obtained homogenates were filtered and centrifuged at 4 °C. After centrifugation, all of the enzymatic activities were determined by using these supernatants. All assays were carried out at room temperature in triplicate (Karakus et al. 2009)

For determination of LPO levels, the thiobarbituric acid test was used as in previous studies (Okhawa et al. 1979; Narayan et al. 2005; Petrović et al. 2008). Malondialdehyde (MDA) was measured spectrophotometrically at 532 nm. The standard curve was drawn by using 1, 1, 3, 3-tetramethoxypropane. The results were expressed as nanomol MDA per gram wet tissue (nmol/g tissue). For determination of GSH levels, we measured the amount of GSH spectrophotometrically at 412 nm (Sedlak and Lindsay 1968). It was expressed as nanomole per milligram tissue (nmol/mg tissue). SOD activity was measured spectrophotometrically at 560 nm (Sun et al. 1988). It was expressed as mmol per minute per mg tissue (mmol/min \times mg tissue). CAT activity was measured spectrophotometrically at 240 nm (Aebi 1984). It was expressed as millimole per minute per milligram tissue (mmol/min \times mg tissue). MPx activity was measured spectrophotometrically at 450 nm (Bradley et al. 1982). It was expressed as micromole per minute per milligram tissue ($\mu\text{mol}/\text{min}/\text{mg}$ tissue). The COX-1 and COX-2 inhibitory assay was performed with a COX Activity Assay Kit according to the manufacturer's protocol. The peroxidase activity of COX is assayed colorimetrically by monitoring appearance of oxidized N,N,N',N' -tetramethyl-*p*-phenylenediamine at 590 nm (Kulmacz and Lands 1983).

Histopathologic examination

For histopathological examination, stomach tissues were rapidly fixed in 10% buffered formalin for 48–72 h. After fixation, each stomach was then routinely processed and embedded in paraffin. After embedding, five sections were taken from the tissues blocks by using a Leica RM2125RT microtome (Leica Microsystems, Wetzlar, Germany). After deparaffinization and rehydration, sections were stained with hematoxylin-eosin (H&E) for histopathological examination. All stomachs were examined by light microscopy for histopathological evaluation of the following parameters: vascular congestion, inflammatory cell infiltrates, hemorrhage, hyalinization, hypertrophic degeneration, necrotic cells.

Statistical analyses

SPSS 20.0 software was used for statistical calculations. One-way variance analyses (ANOVA) were applied to determine the statistical significance of the results. The differences between groups were considered significant at $p < 0.05$.

Results and discussion

Antiulcer effect of PMF on indomethacin-induced gastric damage

PMF substance needed was purified from *Maclura pomifera* plant by TLC method and its structure was elucidated by NMR methods. The antiulcer effect of PMF at doses 100, 200, and 300 mg/kg on indomethacin-induced gastric damage was macroscopically determined in rats (Table 1). Hyperaemias occurred considerably in the stomachs of indomethacin-administrated rats ($p < 0.05$). In the groups treated with PMF and ranitidine, hyperaemias occurred vanishingly small when compared to indomethacin-administrated rats ($p < 0.05$). The group treated with PMF

Table 1 Antiulcer effect of pomiferin (PMF) on indomethacin-induced gastric lesions in rats

Treatment	Dose (mg/kg)	N	Ulcer index (mm ²) ^a
Pomiferin	100	6	4.5 ± 0.43
	200	6	2.17 ± 0.70
	300	6	0.17 ± 0.17
Ranitidine	25	6	4.00 ± 0.58
Indomethacin	25	6	19.83 ± 2.36
Healthy group ^b	–	6	0.00 ± 0.00

N animal number

^a Average values of indomethacin-induced gastric damage

^b Nothing administrated

Table 2 Antioxidant enzymes levels and lipid peroxidation in rat stomach tissues administrated with ranitidin, indomethacin, and PMF

Treatment	Dose (mg/kg)	N	CAT (mmol/min × mg tissue)	SOD (nmol/min/mg tissue)	GSH (nmol/mg tissue)	LPO (nmol/g tissue)
Pomiferin	100	6	195.12 ± 11.61*	1.751 ± 0.058*	0.061 ± 0.0000*	75.63 ± 1.45
	200	6	143.25 ± 5.08	2.057 ± 0.017*	0.070 ± 0.0016*	64.74 ± 2.50*
	300	6	132.28 ± 4.06	2.544 ± 0.189*	0.090 ± 0.0002*	60.07 ± 1.07*
Ranitidine	25	6	162.54 ± 11.57	1.490 ± 0.004*	0.045 ± 0.0007*	80.67 ± 3.53
Indomethacin	25	6	260.91 ± 6.29*	0.991 ± 0.156*	0.037 ± 0.0007*	93.41 ± 2.44*
Healthy group ^a	–	6	155.53 ± 5.66	3.264 ± 0.008*	0.080 ± 0.0003*	74.52 ± 1.52

The measurements were calculated from three replicates. Indomethacin group was compared with the healthy group. PMF and ranitidine groups were compared with indomethacin group

* Significant at $p < 0.05$ according to healthy rats

^a Nothing administrated

at dose of PMF (100 mg/kg) showed the same effect that reduced the ulcer area as the group treated with ranitidine. There was no significant difference between these two groups ($p > 0.05$). Also the antiulcer effect of group treated with PMF (200 mg/kg) were similar in these two groups ($p > 0.05$). The group treated with PMF at dose of PMF (300 mg/kg) when compared to with other groups; there was no significant difference between the group treated with PMF at dose of PMF (200 mg/kg) ($p > 0.05$), but there was a significant difference between the group treated with PMF at dose of PMF (100 mg/kg) and ranitidine ($p < 0.05$). In addition to there was no statistically significant difference between the healthy group and the group treated with PMF (200 and 300 mg/kg) ($p > 0.05$).

The obtained results in this study show that applied doses of PMF and ranitidine had considerable antiulcer effect against gastric damage induced by indomethacin in rats. Ranitidine, which taken as the reference compound, is a H₂-receptor blocker. The antiulcer effect of PMF is much more potent compared with ranitidine.

Biochemical analysis

In order to explore the effects of antioxidant defenses on the ulceration process, in all stomach tissues, the antioxidant levels (LPO, GSH, SOD, and CAT) were evaluated. And also MPx, COX-1 and COX-2 activities are analyzed. The results are given in Tables 2 and 3. This table shows that SOD and GSH levels in indomethacin-administrated groups were lower as compared with healthy rat group. But these levels increased with increasing dose of PMF. GSH level in indomethacin-administrated groups was even higher than the healthy group at dose of PMF (300 mg/kg). However, the levels of CAT and LPO decreased with increasing dose of PMF in indomethacin administrated tissues. These levels in indomethacin-administrated group were even higher than the healthy group and the group treated with PMF at dose of 200 and 300 mg/kg. All doses of PMF compared with

Table 3 MPx, COX-1, and COX-2 activities in rat stomach tissue treated with ranitidin, indomethacin, and PMF

Treatment	Dose (mg/kg)	N	MPx ($\mu\text{mol}/\text{min}/\text{mg}$ tissue)	COX-1 (nmol/min/mg tissue)	COX-2 (nmol/min/mg tissue)
Pomiferin	100	6	95.7063*	3.6388	5.1483
	200	6	71.7797	5.4025	6.8008
	300	6	52.1141*	15.5561*	16.3189*
Ranitidine	25	6	81.2848	2.1769*	2.0975*
Indomethacin	25	6	117.0108*	1.5731*	1.2235*
Healthy group ^a	–	6	71.1242	4.3727	4.9894

The measurements were calculated from three replicates. Indomethacin group was compared with the healthy group. PMF and ranitidine groups were compared with indomethacin group

* Significant at $p < 0.05$ according to healthy rats

^a Nothing administrated

ranitidine had more significant impact in rat stomach (Table 2).

Due to MPx activity widely used as an index of neutrophil infiltration into gastric mucosal tissues, in the present study, the changes of MPx activity in tissues were determined using an appropriate method (Table 3). The MPx level in rats administered indomethacin and PMF did not significantly affect at dose of PMF (100 and 200 mg/kg). But in these rats the MPx level decreased at dose of PMF (300 mg/kg). PMF at dose of (200 and 300 mg/kg) had a greater effect compared with ranitidine taken as the reference compound.

And also COX isoenzymes activities were determined. As can be seen from this Table 3, COX isoenzymes activities decreased significantly in rats administered only indomethacin compared with the healthy group. But PMF increased COX isoenzymes activities in rats administered indomethacin compared with healthy rat tissues, especially at dose of PMF (300 mg/kg). And these increases were much higher than ranitidine.

Histopathologic investigations

The healthy groups had normal histological appearance of the epithelium, glands, lamina propria, muscularis mucosa, and arteries. The larger magnification showed that parietal cells, mucous cells, and chief cells had regular contour (Fig. 1a, b). In ulcer group, there was numerous focal necrotic areas. These necrotic areas possessed coagulative type necrosis and hypertrophic degenerative changes and neutrophil infiltration were existed in glandular cells of its periphery. In addition, vascular congestion, hyalinization, and hemorrhage were observed in this group (Fig. 2a–d). The histopathological changes were significantly reduced in the reference drug group. Also, focal necrotic areas were

less as compared to ulcer group (Fig. 3a, b). There were no focal necrotic areas in PMF-100 group. Although vascular congestion and hypertrophic cell degeneration were observed in mucosal glands, these histopathological changes were considerably less than ulcer group (Fig. 3c, d). In the stomach sections of PMF-200 (Fig. 4a, b) and PMF-300 (Fig. 4c, d), the glands and epithelium lines of mucosa and the cell structure, muscular mucosa structure and vascular appearances were similar to those in healthy group.

In light of the above information, the antiulcerogenic activity of PMF which is a component from the fruit of the *Maclura pomifera* has not been reported. The antiulcerogenic activity of water extract the *Maclura pomifera* has been identified by our group. The two major isoflavone constituents of the the *Maclura pomifera* fruit, osajin, and PMF were reported to possess a number of biological activities (Ozcelik et al. 2006; Kupeli et al. 2006; Florian et al. 2006; Son et al. 2007; Orhan et al. 2009; Carroll et al. 2010; Tran et al. 2011; Yang et al. 2011). However, no report was found on the antiulcerogenic activity of PMF. Thus, we aim to investigate the antiulcerogenic activity effect of PMF on indomethacin-induced gastric damage in rats. As shown in Table 1, the administration of PMF at dose of 100, 200, and 300 mg/kg was significantly reduced the gastric damage compared with the indomethacin-induced group. Dose–response curve was drawn (Fig. 5). And then IC_{50} was determine as 97 mg/kg. All doses of PMF also showed a greater antiulcerogenic effect compared with ranitidine, which is used as a H_2 -receptor blocker.

In some studies recently, important role of ROS in the gastric ulcers pathogenesis caused by the inhibition of COX enzymes, indomethacin, ethanol, and other agents has been shown (Smith and Kviety 1988; Das et al. 1997; Elliot and Wallace 1998; Miura et al. 2002). Due to superoxide radicals produced by peroxidases in the tissues increased the lipid peroxidation, the membranes and stomach tissues may be damaged (Takeuchi et al. 1991; Miura et al. 2002). In this study, we found that there was a significant increase in the LPO level in stomach tissues of rats administered indomethacin. However, there was a significant decrease in the LPO level in stomach tissues of rats administered of all doses of PMF and ranitidine (25 mg/kg body weight). Moreover, against to the lipid peroxidation in tissues organisms have enzymatic and non-enzymatic defenses, such as SOD, CAT, and GSH (Mates et al. 1999). In many studies, the administration of NSAIDs and ethanol has been shown to decrease the levels of GSH, SOD in tissues (Takeuchi et al. 1991; El-Missiry et al. 2001; Bafna and Balaraman 2004). In this study, we found also that the levels of SOD and GSH in stomach tissues of rats administered indomethacin were significantly decreased (Table 2). However, the administration of PMF at dose of 100, 200, and 300 mg/kg and ranitidine (25 mg/kg) caused a

Fig. 1 The histological sections **a, b** of the gastric mucosa in healthy groups (H&E). *M* mucosa, *MM* muscularis mucosa, *MC* mucous, and *G* glandular cells with normal appearance

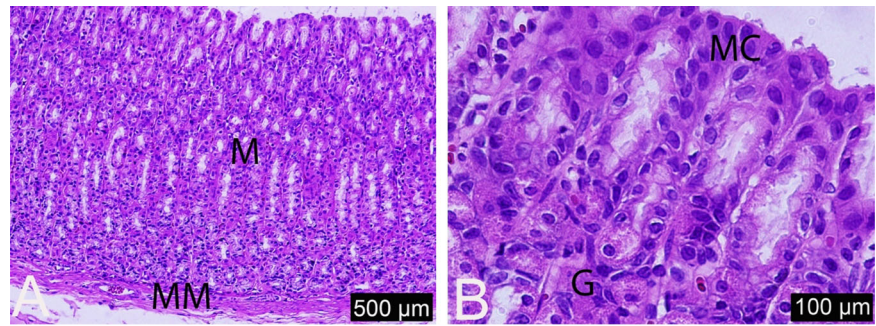
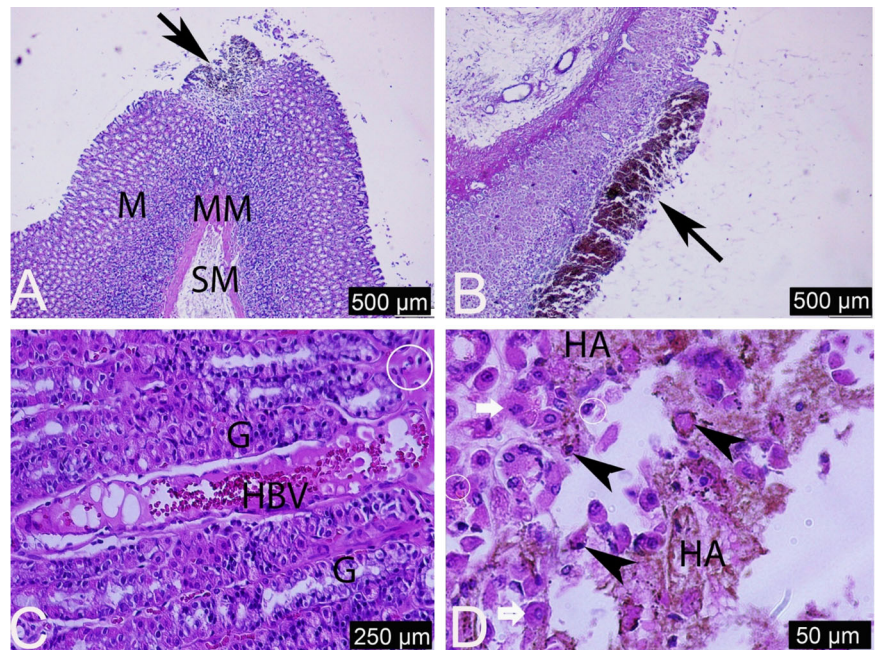


Fig. 2 The histological sections **a–d** of the gastric mucosa in ulcer groups (H&E). *Black arrows* focal necrotic areas, *Black arrow heads* glandular or epithelial necrotic cells, *White arrows* hypertrophic glandular cells, *White circles* neutrophil infiltration, *HA* hemorrhagic area, *M* mucosa, *SM* submucosa, *MM* muscularis mucosa, *HBV* hyalinized blood vessels, *G* gland



significant increase the SOD and GSH levels in stomach tissues. Moreover, according to our results, the levels of CAT were found to be increased in stomach tissues of rats administered indomethacin as compared with tissues of healthy rat (Table 2). This increase may be due to an increase in the mucosal H_2O_2 and OH^- level, occurred by inhibition of peroxidases (Banarjee 1990). When we applied all doses of PMF, the activity of this enzyme decreased. It may be due to the decrease H_2O_2 and OH^- levels in the tissue. In light of these results, we thought that PMF and ranitidine show effect of reducing oxidative damage in rat stomach tissues.

Myeloperoxidase (MPx) activity in the gastric mucosa is an index of neutrophil infiltration. The neutrophil infiltration into the gastric mucosal tissues can be checked by MPx (Yoshida et al. 1995). The increase of this enzyme activity means that there is an increase in the level of neutrophil infiltration into the gastric damaged tissues. In this study, our results showed that the administration of indomethacin significantly increased the level of MPx in tissues ($p < 0.05$). In light of these results, we thought that indomethacin

caused the neutrophil-infiltration into the stomach tissues. Also some scientists obtained similar results in many studies (Yoshida et al. 1995; Takeuchi et al. 1997; Khattab et al. 2001; Odabasoglu et al. 2006). In contrast to indomethacin, in this study, the administration of PMF showed the opposite effect (Table 3). There was no significant difference between the healthy group with the group treated with ranitidine and PMF at dose of 200 mg/kg ($p > 0.05$). However, there was significant difference between the healthy group and the group treated with PMF at dose of 300 mg/kg ($p < 0.05$). This difference means that the PMF at dose of 300 mg/kg is reduced the level of MPx in tissues compared to the healthy group.

The gastric ulcer production by indomethacin is due to the fact that this compound inhibits the synthesis of cytoprotective prostaglandins, synthesized by COX-1 and COX-2 in the stomach tissue (De Souza et al. 2002). But our results showed that all dose of PMF activated COX isoenzymes. Due to the activation of cytoprotective prostaglandins with PMF, cytoprotection in gastric mucosa was increased.

Fig. 3 The histological sections of the gastric mucosa in references groups **a, b**, and PMF-100 groups **c, d** (H&E). *NA* necrotic area, *Black arrows* necrotic glandular or epithelial cells, *BV* blood vessels, and *G* gland with hypertrophic cells in references groups. *G* gland, *BV* blood vessels, and *White arrows* hypertrophic parietal cells in PMF-100 groups

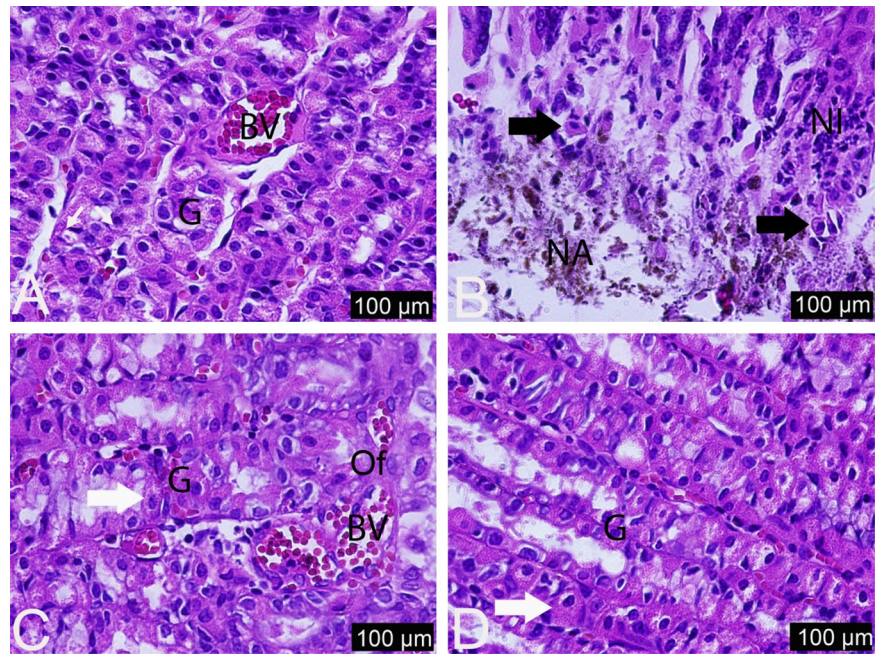
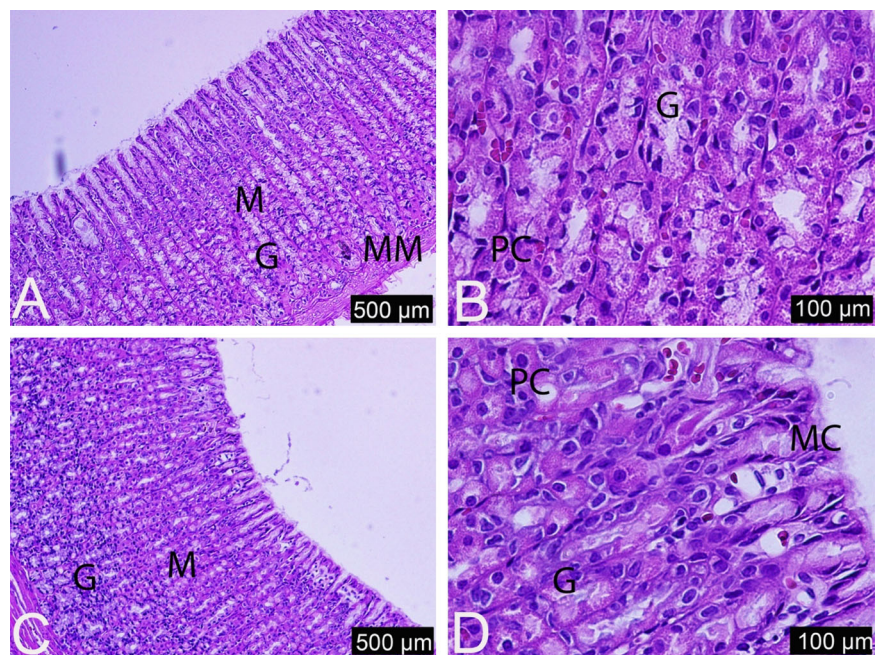


Fig. 4 The histological sections of the gastric mucosa in PMF-200 groups **a, b** and PMF-300 groups **c, d** (H&E). *M* mucosa, *MM* muscularis mucosa, *G* gland, *MC* mucous cells, and *PC* parietal cells with normal appearance in both the treatment groups



In the ulcer group, coagulative necrosis was observed, which is a cell death and usually occurs in a tissue due to arterial vasoconstriction-related hypoxia. Therefore, the reason of this type of cell necrosis in ulcer group could be due to the vasoconstrictor effect of indomethacin, as previously mentioned in the literature (Hadházy and Nádor 1976; Friedman et al. 1981; Lipton et al. 1987). Apart from necrotic area, inflammation and hypertrophic cell damage were observed, which could be due to increased

ROS types in tissues. PMF reduced the histopathological damage in dose-dependent manner, which could be due to either activation of the antioxidant defense system or decrease in local vasoconstriction

In conclusion, all doses of PMF showed a significant gastroprotective effect in the indomethacin-induced gastric damage in rats. PMF toxicity was not observed in the literature. It can be undoubtedly designed as a drug. We conclude that the gastroprotective effect of PMF can be

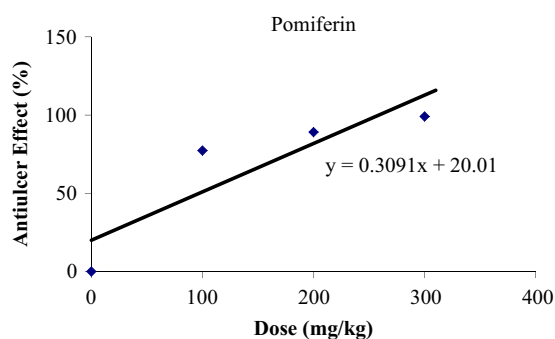


Fig. 5 Dose–response curve for the determination of IC_{50}

postulated oxidative damage reduction, neutrophil infiltration inhibition in stomach rat tissues, and COX isoenzymes activation.

Acknowledgements This study was supported by The Scientific and Technological Research Council of Turkey (TUBITAK, Project Number: 213S114) and Research Fund of Erzincan University (Project number: SAG-A-300614-0100). We are grateful to the TUBITAK and Erzincan University for financial support.

Compliance with Ethical Standards

Conflict of interest The authors declare that they have no competing interests.

References

- Aebi H (1984) Catalase in vitro. *Methods Enzymol* 105:121–126
- Ames BN, Shigenaga MK, Hagen TM (1993) Oxidants, antioxidants, and the degenerative diseases of aging. *Proc Natl Acad Sci USA* 90:7915–7922
- Atalay F, Halici MB, Mavi A, Cakir A, Kazaz C, Aslan A, Kufrevioglu OI (2011) Antioxidant phenolics from *Lobaria pulmonaria* (L.) Hoffm. and *Usnea longissima* Ach. Lichen species. *Turk J Chem* 35:647–661
- Bafna PA, Balaraman R (2004) Anti-ulcer and antioxidant activity of DHC- 1, a herbal formulation. *J Ethnopharmacol* 90:123–127
- Banerjee RK (1990) Non-steroidal anti-inflammatory drugs inhibit gastric peroxidase activity. *Biochim Biophys Acta* 1034:275–279
- Bourdy G, Chavez de Michel LR, Roca-Coulthard A (2004) Pharmacopoeia in a shamanistic society: the Izoceno-Guarani (Bolivian Chaco). *J Ethnopharmacol* 91:189–208
- Bradley PP, Priebat DA, Christensen RD, Rothstein G (1982) Measurement of cutaneous inflammation: estimation of neutrophil content with an enzyme marker. *J Invest Dermatol* 78:206–209
- Carroll J, Paluch J, Coats J, Kramer M (2010) Elemol and amyris oil repel the ticks *Ixodesscapularis* and *Amblyommaamericanum* (Acari: Ixodidae) in laboratory bioassays. *Exp Appl Acarol* 51:383–392
- Chatterjee A, Khatua S, Chatterjee S, Mukherjee S, Mukherjee A, Paloi S, Acharya K, Bandyopadhyay SK (2013) Polysaccharide-rich fraction of *Termitomyces eurhizus* accelerate healing of indomethacin induced gastric ulcer in mice. *Glycoconj J* 30:759–768
- Coskun T, Yegen BC, Alican I, Peker O, Kartel H (1996) Cold restraint stress-induced gastric mucosal dysfunction-role of nitric oxide. *Dig Dis and Sci* 41:956–963
- Das D, Bandyopadhyay D, Bhattacharjee M, Banerjee RK (1997) Hydroxyl radical is the major causative factor in stress-induced gastric ulceration. *Free Radic Biol Med* 23:8–18
- Das D, Banerjee RK (1993) Effect of stress on the antioxidant enzymes and gastric ulceration. *Mol Cell Biochem* 125:115–125
- De Souza GE, Cardoso RA, Melo MC, Fabricio AS, Silva VM, Lora M, De Brum Fernandes AJ (2002) A comparative study of the antipyretic effects of indomethacin and dipyron in rats. *Inflamm Res* 51:24–32
- Djahanguiri B (1968) The production of acute gastric ulceration by indomethacin in the rat. *Scand J Gastroenterol* 4:265–267
- Elliot SN, Wallace JL (1998) Neutrophil-mediated gastrointestinal injury. *Can J Gastroenterol* 12:559–568
- El-Missiry MA, El-Sayed IH, Othman AI (2001) Protection by metal complexes with SOD-mimetic activity against oxidative gastric injury induced by indomethacin and ethanol in rats. *Ann Clin Biochem* 38:694–700
- Farrow DC, Vaughan TL, Sweeney C, Gammon MD, Chow W-H, Risch HA, Stanford JL, Hansten PD, Mayne ST, Schoenberg JB (2000) Gastroesophageal reflux disease, use of H2 receptor antagonists, and risk of esophageal and gastric cancer. *Cancer Causes Control* 11:231–238
- Florian T, Necas J, Bartosikova L, Klusakova J, Suchy V, El Naggari EB, Janostikova E, Bartosik T (2006) Effects of prenylatedisoflavonesosajin and pomiferin in premedication on heart ischemia reperfusion. *Biomed Pap Med Fac Univ Palacky Olomouc Czech Repub* 150:93–100
- Friedman PL, Brown Jr EJ, Gunther S, Alexander RW, Barry WH, Mudge Jr GH, Grossman W (1981) Coronary vasoconstrictor effect of indomethacin in patients with coronary-artery disease. *N Engl J Med* 305(20):1171–1175
- Gray SL, LaCroix AZ, Larson J, Robbins J, Cauley JA, Manson JE, Chen Z (2010) Proton pump inhibitor use, hip fracture, and change in bone mineral density in postmenopausal women: results from the Women’s Health Initiative. *Arch Intern Med* 170:765–771
- Guidobono F, Pagani F, Ticozzi C, Sibilina V, Pecile A, Netti C (1997) Protection by amylin of gastric erosions induced by indomethacin or ethanol in rats. *Br J Pharmacol* 120:581–586
- Hadházy P, Nádor T (1976) Effects of indomethacin and PGE1 on the vasoconstrictor responses of the rabbit ear artery to nerve stimulation. *Prostaglandins* 11(2):241–250
- Hawkey CJ (1990) Non-steroidal anti-inflammatory drugs and peptic ulcers: facts and figures multiply, but do they add up? *BMJ* 300:278–284
- Jalving M, Koornstra J, Wesseling J, Boezen H, De Jong S, Kleibeuker J (2006) Increased risk of fundic gland polyps during long-term proton pump inhibitor therapy. *Aliment Pharmacol Ther* 24:1341–1348
- Jones JM, Soderberg F (1979) Cytotoxicity of lymphoid cells induced by *Maclura pomifera* (MP) lectin. *Cell Immunol* 42:319–326
- Karakus B, Odabasoglu F, Cakir A, Halici Z, Bayir Y, Halici M, Aslan A, Suleyman H (2009) The effects of methanol extract of *Lobaria pulmonaria*, a lichen species, on indometacin-induced gastric mucosal damage, oxidative stress and neutrophil infiltration. *Phytother Res* 23:635–639
- Khattab MM, Gad MZ, Abdallah D (2001) Protective role of nitric oxide in indomethacin-induced gastric ulceration by a mechanism independent of gastric acid secretion. *Pharmacol Res* 43:463–467
- Kulmacz RJ, Lands WE (1983) Requirements for hydroperoxide by the cyclooxygenase and peroxidase activities of prostaglandin H synthase. *Prostaglandins* 25(4):531–540
- Kupeli E, Orhan I, Toker G, Yeşilada E (2006) Anti-inflammatory and antinociceptive potential of *Maclura pomifera* (Rafin.) Schneider fruit extracts and its major isoflavonoids, scandenone and auricularin. *J Ethnopharmacol* 107:169–174

- Lippton HL, Armstead WM, Hyman AL, Kadowitz PJ (1987) Characterization of the vasoconstrictor activity of indomethacin in the mesenteric vascular bed of the cat. *Prostaglandins Leukot Med* 27 (1):81–91
- Marcus GM, Smith LM, Scheinman MM, Badhwar N, Lee R (2010) Proton pump inhibitors are associated with focal arrhythmias. *JICRM* 1:85–89
- Mates JM, Perez-Gomez C, Nudes de Castro I (1999) Antioxidant enzymes and human diseases. *Clin Biochem* 32:595–603
- Miura T, Muraoka S, Fujimoto Y (2002) Lipid peroxidation induced by indomethacin with horseradish peroxidase and hydrogen peroxide: involvement of indomethacin radicals. *Biochem Pharmacol* 63:2069–2074
- Narayan S, Devi RS, Srinivasan P, Shyamala Devi CS (2005) Pterocarpus santalinus: a traditional herbal drug as a protectant against ibuprofen induced gastric ulcers. *Phytother Res* 19:958–962
- Navarete A, Martínez-Urbe LS, Reyes B (1998) Gastroprotective activity of the stem bark of *Amphipterygium adstringens* in rats. *Phytother Res* 12:1–4
- Nishida K, Ohta Y, Ishiguro I (1998) Contribution of NO synthases to neutrophil infiltration in the gastric mucosal lesions in rats with water immersion restraint stress. *FEBS Lett* 425:243–248
- Odabasoglu F, Cakir A, Suleyman H, Aslan A, Bayir Y, Halici M, Kazaz C (2006) Gastroprotective and antioxidant effects of usnic acid on indomethacin-induced gastric ulcer in rats. *J Ethnopharmacol* 103:59–65
- Okhawa H, Ohishi H, Yagi K (1979) Assay for lipid peroxide in animal tissues by thiobarbituric acid reaction. *Anal Biochem* 95:351–358
- Orhan I, Senol FS, Kartal M, Dvorska M, Zemlicka K, Smejkal K, Mokry P (2009) Cholinesterase inhibitory effects of the extracts and compounds of *Maclura pomifera* (Rafin.) Schneider. *Food Chem Toxicol* 47:1747–1751
- Ozcelik B, Orhan I, Toker G (2006) Antiviral and antimicrobial assessment of some selected flavonoids. *Z Naturforsch C* 61:632–638
- Peskar BM (2001) Role of cyclooxygenase isoforms in gastric mucosal defence. *J Physiol Paris* 95:3–9
- Petrović S, Dobrić S, Mimica-Dukić N, Simin N, Kukić J, Niketić M (2008) The antiinflammatory, gastroprotective and antioxidant activities of *Hieracium gymnocephalum* extract. *Phytother Res* 22:1548–1551
- Sedlak J, Lindsay RH (1968) Estimation of total, protein-bound, and nonprotein sulfhydryls groups in tissue with Ellman's reagent. *Anal Biochem* 25:192–205
- Smith JL, Perino JV (1981) Osage orange (*Maclura pomifera*): history and economic uses. *Econ Bot* 35:24–41
- Smith SM, Kvietys PR (1988) Gastric ulcers: role of oxygen radicals. *Crit Care Med* 16:892–898
- Son IH, Chung IM, Lee SI, Yang HD, Moon HI (2007) Pomiferin, histone deacetylase inhibitor isolated from the fruits of *Maclura pomifera*. *Bioorg Med Chem Lett* 17:4753–4755
- Sun Y, Larry WO, Ying L (1988) A simple method for clinical assay of superoxide dismutase. *Clin Chem* 34:497–500
- Sung J, Kuipers E, El-Serag H (2009) Systematic review: the global incidence and prevalence of peptic ulcer disease. *Aliment Pharmacol Ther* 29:938–946
- Takeuchi K, Kato S, Yasuhiro T, Yagi K (1997) Mechanism of acid secretory changes in rat stomach after damage by taurocholate: role of nitric oxide, histamine, and sensory neurons. *Dig Dis Sci* 42:645–653
- Takeuchi K, Ueshima K, Hironaka Y, Fujioka Y, Matsumoto J, Okabe S (1991) Oxygen free radicals and lipid peroxidation in the pathogenesis of gastric mucosal lesions induced by indomethacin in rats. Relation to gastric hypermotility. *Digestion* 49:175–184
- Tran VH, Marks D, Duke RK, Bebawy M, Duke CC, Roufogalis BD (2011) Modulation of P-glycoprotein-mediated anticancer drug accumulation, cytotoxicity, and ATPase activity by flavonoid interactions. *Nutr Cancer* 63:435–443
- Tsao R, Yang R, Young JC (2003) Antioxidant isoflavones in osage orange *Maclura pomifera* (Raf.) Schneid. *J Agric Food Chem* 51:6445–6451
- Yang R, Hanwell H, Zhang J, Tsao R, Meckling KA (2011) Anti-proliferative activity of pomiferin in normal (MCF-10A) and transformed (MCF-7) breast epithelial cells. *J Agric Food Chem* 59:13328–13336
- Yoshida H, Mamada Y, Taniai N, Mineta S, Kawano Y, Mizuguchi Y, Kakinuma D, Kanda T, Tajiri T (2008) Interactions between anti-ulcer drugs and non-steroidal anti-inflammatory drugs in cirrhotic patients with bleeding esophagogastric varices. *Hepato Gastroenterol* 56:1366–1370
- Yoshida N, Yoshikawa T, Nakamura Y, Arai M, Matsuyama K, Inuma S, Nishimura S, Kondo M (1995) Role of neutrophil-endothelial cell interactions in gastric mucosal injury induced by aspirin. *J Clin Gastroenterol* 21:73–77