To cite this article: Yazkan R, Çeviker K, Aydı B, İlhan AA, Çiriş İM. Parathyroid adenoma located on anterior mediastinum. Turk J Clin Lab 2016; 7(3): 83-85.

Case Report

Parathyroid adenoma located on anterior mediastinum

Anterior mediasten yerleşimli paratiroid adenomu

Rasih YAZKAN[1a], Kadir ÇEVİKER[2], Bünyamin AYDIN[3], Azime Aslıhan İLHAN[4], İbrahim Metin ÇİRİŞ[5]

[1]Süleyman Demirel University, School of Medicine, Department of Thoracic Surgery, Isparta,
[2] Süleyman Demirel University, School of Medicine, Department of Cardiovascular Surgery, Isparta,
[3]Süleyman Demirel University, School of Medicine, Department of Endocrinology, Isparta,
[4] Süleyman Demirel University, School of Medicine, Department of Nuclear Medicine, Isparta,
[5]Süleyman Demirel University, School of Medicine, Department of Pathology, Isparta, Isparta,TURKEY

ABSTRACT

The real incidence of parathyroid lesions causing primary hyperparathyroidism is unclear. Adenomas are the most common cause and constitute 75-80% of the cases. Benign hyperplasia is responsible for 10-15%, and the parathyroid carcinoma less than 5%. Parathyroid adenomas causing hyperparathyroidism may present an ectopic localization at 20-25% of the patients. Here we discuss a case of symptomatic hypercalcemia, due to an ectopic parathyroid adenoma in the anterior mediastinum. She was treated by excision of the ectopic parathyroid along with thymectomy, approached by median sternotomy. Serum calcium and parathyroid hormone levels were normalized immediately after surgery.

Key words: Parathyroid diseases, ectopic, primary hyperparathyroidism, mediastinum

ÖZ

Primer hiperparatroidizme sebep olan paratroid lezyonlarının gerçek insidansı belirsizdir. Olguların en sık nedenini %75-80 adenomlar oluşturmaktadır. Benign hiperplaziler %10-15'inden, paratroid karsinomları ise %5'den azından sorumludurlar. Hiperparatroidizme neden olan paratroid adenomlarının %20-25'i ise ektopik yerleşimlidir. Biz bu olgu sunumunda anterior mediastende yer alan ektopik paratroid adenomu nedeniyle semptomatik hiperkalsemili olguyu tartıştık. Olguya medyan sternotomi aracılığıyla timektomi ile ektopik paratiroid rezeksiyonu uygulandı. Serum kalsiyum ve parathormon seviyeleri hızlı bir biçimde geriledi.

Anahtar kelimeler: Paratroid hastalıkları, ektopik, primer hiperparatroidizm, mediasten

Corresponding Author [a]: Rasih Yazkan, MD. Süleyman Demirel University, School of Medicine, Department of Thoracic Surgery, Isparta, TURKEY
Phone: 0090 505 483 59 61 e-mail: drrasihyazkan@yahoo.com
Received 15.09.2015, accepted 16.12.2015
doi. 10.18663/tjcl.19457

Volume 7 Number 3 p: 83-85

Introduction

The real incidence of parathyroid lesions causing primary hyperparathyroidism is unclear. Adenomas are the most common causes constituting 75-80 % of the cases. Benign hyperplasia is responsible for 10-15%, and the parathyroid carcinoma less than 5%. Histopathologic examination of mediastinal parathyroid lesions do not differ from cervical parathyroid glands [1]. Ectopic parathyroid adenomas represent a diagnostic challenge, since they are extremely rare in clinical practice [2]. Parathyroid adenomas causing to hyperparathyroidism may present an ectopic localization at 20-25% of the patients [3,4]. 5-10% of ectopically located adenomas are seen at posterior mediastinum, 20% at substernal localization and 1-2% at anterior mediastinum and at the lower levels from the manubrium [3]. Presence of the mediastinal located parathyroid adenoma usually indicates the presence of multiple number of parathyroid gland. Persisting high calcium levels at postoperative period are related to ectopic and/or higher number of parathyroid glands [3]. Localization should be defined through the methods such as Tc-99m MIBI or Single Photon Emission Computed Tomography and the appropriate surgery should be performed [3].

Here we discuss a case of symptomatic hypercalcemia, due to an ectopic parathyroid adenoma in the anterior mediastinum. She was treated by ectopic parathyroid removal along with thymectomy via median sternotomy approached. Serum calcium and parathyroid hormone levels were normalized immediately after surgery.

Case Report

A 41-year-old female patient presented to thoracic surgery department with an anterior mediastinal mass. She was on control endocrinology department with a four-year history symptom of primary hyperparathyroidism including nephrolithiasis, common bone pain, nausea, vomiting, chronic fatigue and constipation. In laboratory examinations; calcium (Ca+) levels were defined as 13.5 mg/dl; phosphorus levels as 1 mg/dl and parathyroid hormone levels as 146.7 pg/ml. Parathyroid ultrasonography was normal and bone densitometry was within normal limits. On parathyroid scintigraphy performed with Tc99-m MIBI and increased focal uptake was found in mediastinum suggesting a parathyroid adenoma (Figure 1). Computed thoracic tomography demonstrated a mass of 6 mm anterior to aortic arch with marked contrast enhancement (Figure 2). The patient was operated on with these findings. She was treated by ectopic parathyroid removal along with thymectomy, via a median sternotomy approach (Figure 3). We used the gamma probe for detected the parathyroid adenoma. Serum calcium and parathyroid hormone levels were normalized immediately at postoperative day 1, in laboratory examinations calcium (Ca+) levels were defined as 8.7 mg/dl; phosphorus levels as 3 mg/dl and parathyroid hormone levels as 10.04 pg/ml. Pathological evaluation was consistent with parathyroid adenomas 8 mm in diameter (Figure 4). The patient was discharged uneventfully.

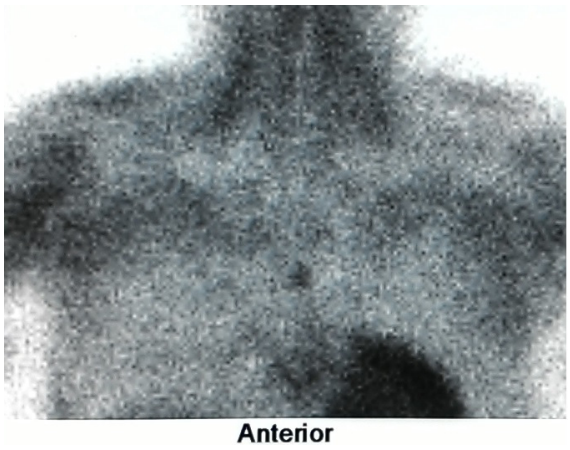

Figure 1. Increased focal uptake in mediastinum (suspected parathyroid adenoma) is showing on parathyroid scintigraphy.



Figure 2. A mass of about 6 mm which marked contrast was detected on aortic arch anterior localization in chest computed tomography.

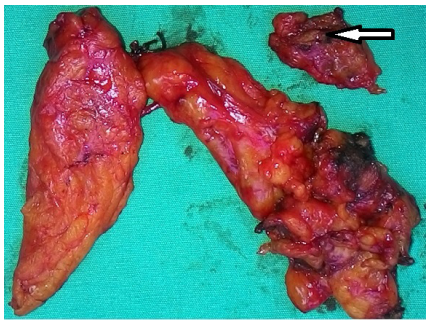

Figure 3. Postsurgical resection material: Ectopic parathyroid (white arrow) removal along with thymectomy.

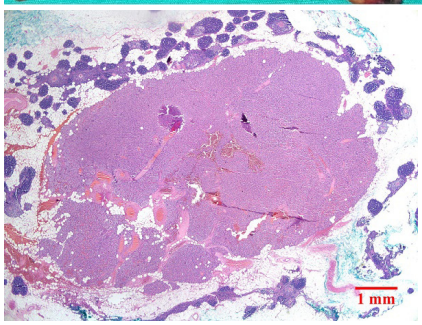

Figure 4. Ectopic parathyroid adenoma in the thymus. Section shows the chief cell type a solid growth pattern. H&E stain 20x

Discussion

Ectopic parathyroid glands are more frequently found in females than in males (3:1) [2]. Hypercalcemia and hypophosphatemia are manifestations of excessive secretion of the parathyroid hormone [2]. Mediastinal parathyroid glands cause hyperparathyroidism in 20% of all patients with primary hyperparathyroidism, and these glands have been incompletely removed when using the cervical approach in 2% of all patients [2,5]. Parathyroid hormone and Ca+ levels of primary hyperparathyroidism patients are above the normal limits and there is no secondary pathology that will cause an increase. The symptoms and findings at these patients are seen after the increase of Ca+ blood levels due to

destruction from the bones and simultaneously increasing of Ca+ excretion with the urine. Hypercalciuria and concomitant renal calculus occurrence, bone diseases seen after decreasing of Ca+ levels (bone cysts, osteitis fibrosa cystica, Brown tumor, bone fractures, pains), gastrointestinal system pathologies associated with the severity of hypercalciuria (anorexia, weight loss, nausea, vomiting) and skeletal muscle system pathologies may be seen at primary hyperparathyroidism [3].

The most noninvasive diagnostic method for mediastinal parathyroid glands is contrast enhanced computed tomography. However, parathyroid glands that measure less than 1.5 cm are difficult to identify by computed tomography. Ultrasonography, magnetic resonance imaging, positron emission tomography, and single photon emission computed tomography are also very helpful in the diagnosis of ectopic parathyroid glands, however the most reliable and practical noninvasive diagnostic technique is currently a Tc-99m MIBI scan because it has the highest detection rate [2,6].

However while Tc99-m MIBI has a sensitivity of 78% at hyperparathyroidism, sensitivity of SPECT is 96%. Furthermore while lesions less than 1 gr can be easily identified with SPECT, out-comes of Tc99-m MIBI are related to gland size and Ca+ levels. It may not detected the minor glands [3,7]. However Tc99-m MIBI has become the most used method, because SPECT is usually insufficient to define the lesions and is not available in most of the centers. Sensitivity of CT and MRI for mediastinal located adenomas is 42- 68% and 77- 82% respectively [3,8]. Although ultrasound is usually a practical method for lesions at cervical region, its sensitivity at mediastinal located lesion is 12-18% [3,9]. The radiological studies at recurrent parathyroid adenomas have found positive predictive values as 60- 92% for ultrasound, 78- 100% for Sestamibi, 36- 100% for CT, 51- 100% for MRI and 70- 74% for PET [3,10].

The most popular treatment method for ectopic parathyroid glands is surgical excision via a cervical incision. However, this approach is not suitable when the parathyroid gland is located in either the anterior or posterior mediastinum [2]. A median sternotomy or thoracotomy have traditionally been used to treat such cases, but many surgeons have recently performed minimally invasive surgical techniques such as video assisted thoracoscopic surgery (VATS) and video assisted mediastinoscopy (VAM) and achieved surgical outcomes similar to those associated with the traditional surgical approach. These techniques have the advantages of short hospital stays, cost effectiveness with a minimal and comfortable incision [2].However, there is still debates whether the extensive thymectomy is eligible or not. We preferred the median sternotomy for extensive thymectomy, due to the small lesion of 6 mm.

Today there are publications related to intraoperative gamma probe use at the parathyroid adenomas surgery [3,8]. It is possible to quickly define the lesions with gamma probe use [3]. In our case we used the gamma probe for detection the parathyroid adenoma.

Another option for the treatment of an ectopic parathyroid gland in the mediastinum is angiographic ablation. So far this method is most minimally invasive treatment option, but it has a success rate of just 40% [2,11].

In conclusion, adenoma is a common cause of primary hyperparathyroidism which may be seen at mediastinum as an ectopic location. These lesions often can be detected with Tc99-m MIBI and should be surgically removed either via a median sternotomy, thoracotomy, mediastinotomy, mediastinoscopy or thoracoscopy and intraoperative use of gamma probe is helpful for detection of adenomas.

Declaration of conflicting interests

The authors declared no conflicts of interest with respect to the authorship and/or publication of this article.

Funding

The authors received no financial support for the research and/or authorship of this article.

References

1. Enön S. Mediastenin endokrin tümörleri. Toraks Cerrahisi Bülteni 2011; 2: 124-35.
2. Lee WS, Kim YH, Lee SA, Chee HK, Hwang JJ. Hyperparathyroidsm induced by heterotopic parathyroid adenoma in the anterior mediastinum. Turk Gogus Kalp Dama 2014; 22: 443-6.
3. Çelik A, Aydın E, Yazıcı Ü, Karaoğlanoğlu N. Parathyroid adenoma located on anterior mediastinum and Hungry Bone Syndrome; Case Report. J Clin Anal Med 2014; 5: 69-71.
4. Thompson NW, Eckhauser F, Harness J. The anatomy of primary hyperparathyroidism. Surgery 1982; 92: 814-21.
5. Soler R, Bargiela A, Cordido F, Aguilera C, Argüeso R, Cao I. MRI of mediastinal parathyroid cystic adenoma causing hyperparathyroidism. J Comput Assist Tomogr 1996; 20: 166-8.
6. Uludag M, Isgor A, Yetkin G, Atay M, Kebudi A, Akgun I. Supernumerary ectopic parathyroid glands. Persistent hyperparathyroidism due to mediastinal parathyroid adenoma localized by preoperative single photon emission computed tomography and intraoperative gamma probe application. Hormones (Athens) 2009; 8:144-9.
7. Moriyama T, Kageyama K, Nigawara T, et al. Diagnosis of a case of ectopic parathyroid adenoma on the early image of 99mTc- MIBI scintigram. Endocr J 2007; 54: 437-40.
8. Uludag M, Isgor A, Yetkin G, Atay M, Kebudi A, Akgun I. Supernumerary ectopic parathyroid glands. Persistent hyperparathyroidism due to mediastinal parathyroid adenoma localized by preoperative single photon emission computed tomography and intraoperative gamma probe application. Hormones (Athens) 2009; 8: 144-9.
9. Al-Mashat F, Sibiany A, Faleh D, Kary K, Alfi AY, El-Lakany MM. Mediastinal para-thyroid adenoma. Saudi J Kidney Dis Transpl 2009; 20: 826-30.
10. Johnson NA, Tublin ME, Ogilvie JB. Parathyroid imaging: technique and role in the preoperative evaluation of primary hyperparathyroidism. AJR Am J Roentgenol 2007; 188: 1706-15.
11. Tcherveniakov P, Menon A, Milton R, Papagiannopoulos K, Lansdown M, Thorpe JA. Video-assisted mediastinoscopy (VAM) for surgical resection of ectopic parathyroid adenoma. J Cardiothorac Surg 2007; 2: 41.